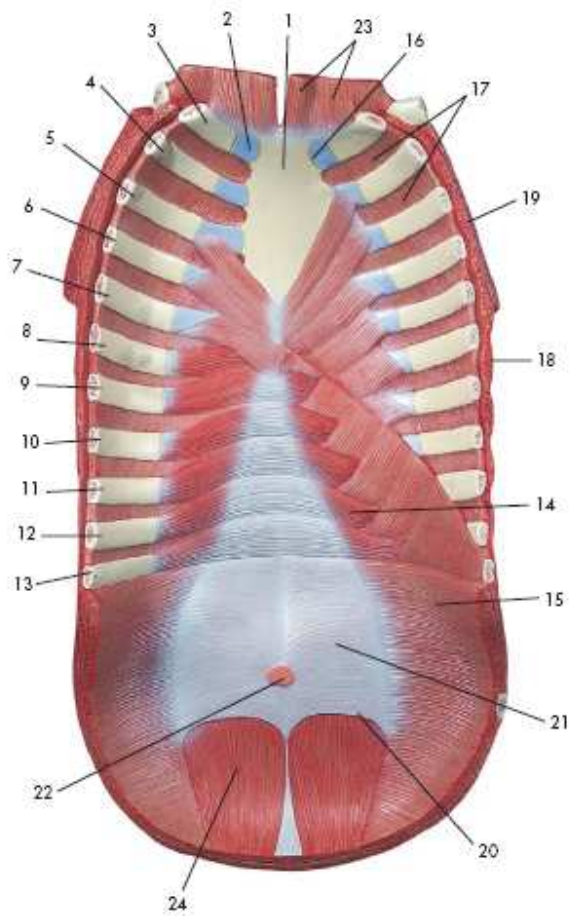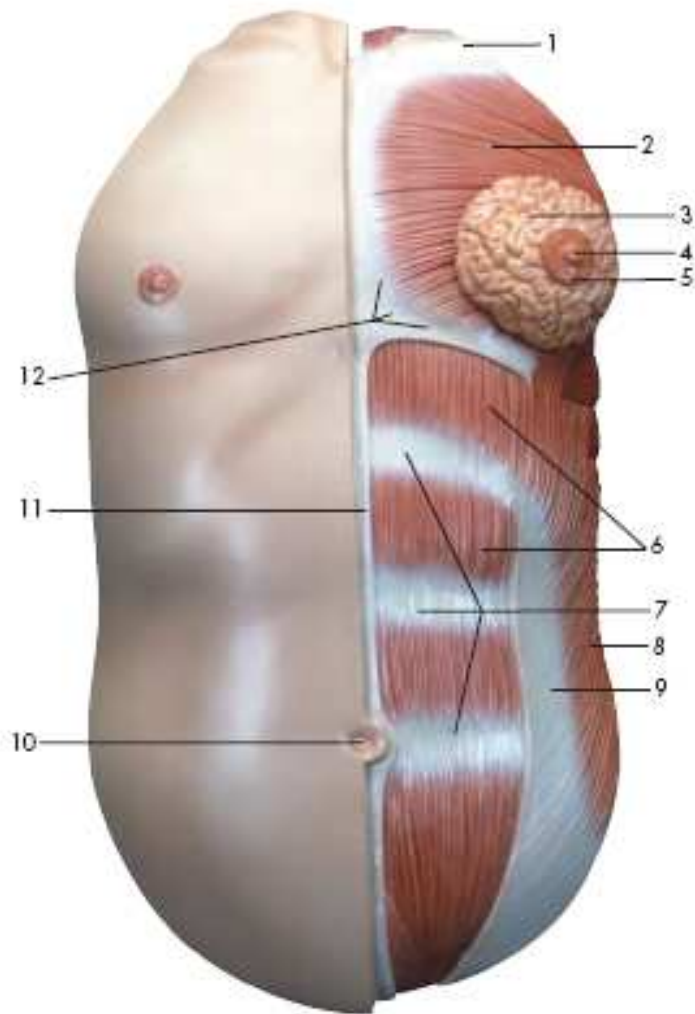


Chest Wall Muscles

- 1. Manubrium of sternum
- 15. Transversus abdominis muscle
- 17. Internal intercostal muscles
- 18. Serratus anterior muscle
- 19. Pectoralis major muscle
- 21. Sheath of rectus abdominis muscle
- 23. Sternocleidomastoideus muscle
- 24. Rectus abdominis muscle



Abdominal wall muscles

1. Clavicle
2. Pectoralis major muscle
3. Nipple
4. Areola
5. Mammary gland
6. Rectus abdominis muscle
7. Tendinous intersection
8. Obliquus externus abdominis muscle
9. Sheath of rectus abdominis muscle
10. Umbilicus
11. White line of abdomen (linea alba)
12. External oblique muscle